

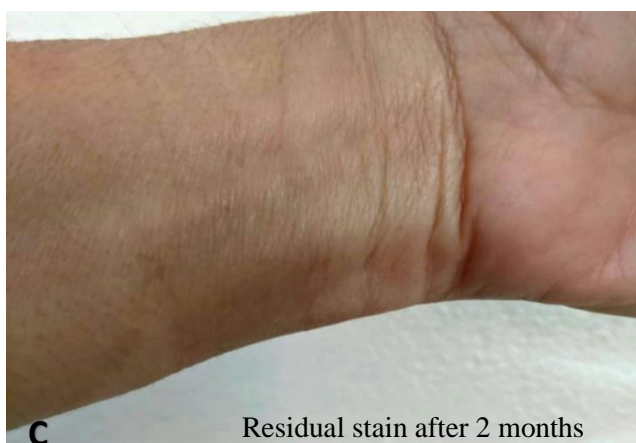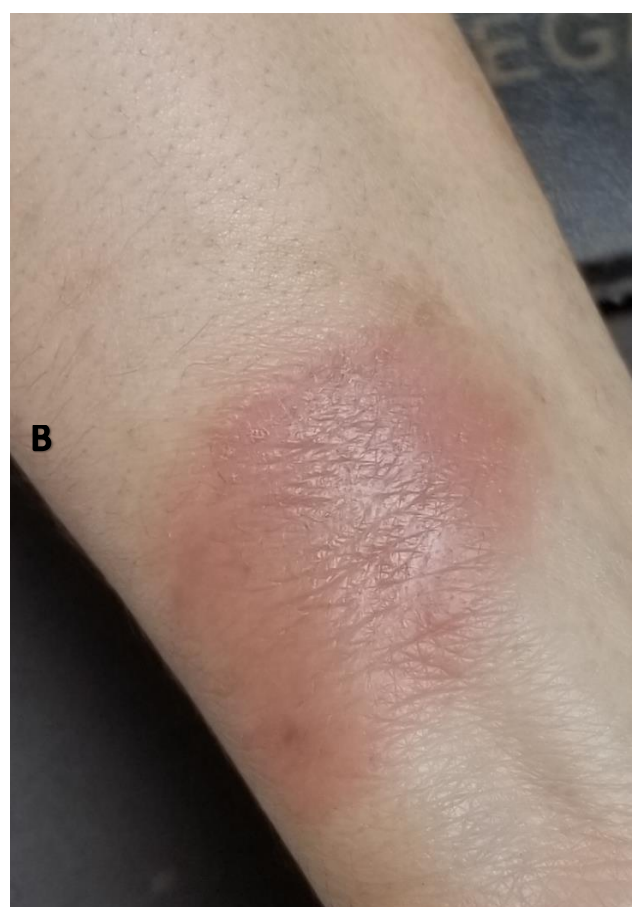
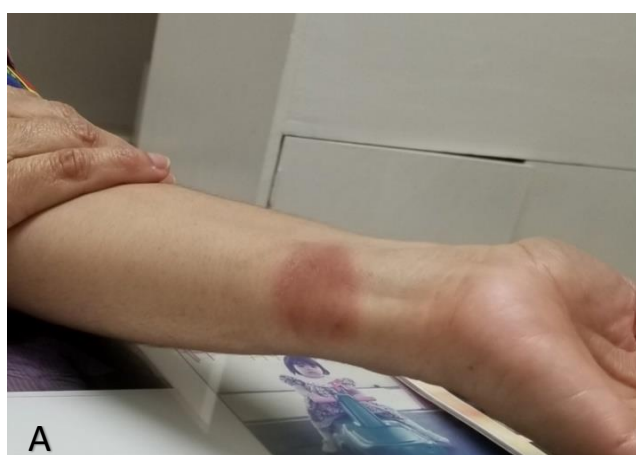Image

Ivermectin-induced fixed drug eruption: a rare adverse event

Eritema fijo medicamentoso inducido por ivermectina: un evento adverso raro

Alicia Mejía de Calona,¹ Odessa Henríquez Rivas

Investigadora Independiente, Tegucigalpa, Honduras



On January 2021, a 62-year-old woman complained of “allergy” in her forearm. She had taken generic ivermectin (IVM) 6mg per week as COVID-19 prophylaxis for two weeks before the eruption. She stopped the medication and improved, but symptoms reactivated after IVM was restarted (A). On examination, there was a 4 cm diameter erythematous violaceous plaque. There was improvement after treatment with oral prednisolone and topical betamethasone (B & C). The patient had presented paracetamol-related eruption in her tongue some years before. Physicians should be aware of ivermectin-induced fixed drug eruption, since this drug is being widely used during the COVID-19 pandemic.

¹Autor corresponsal: aliciadecalona@yahoo.com, Tegucigalpa, Honduras

Historia del Artículo: Recibido: 7 de abril 2021; Revisado: 8 de abril 2021; Aceptado: 9 de abril 2021; Disponible en línea: 30 de abril 2021

Disponible en <https://doi.org/10.5377/innovare.v10i1.11414>

© 2021 Autores. Este es un artículo de acceso abierto publicado por UNITEC bajo la licencia <http://creativecommons.org/licenses/by-nc-nd/4.0>