

Image

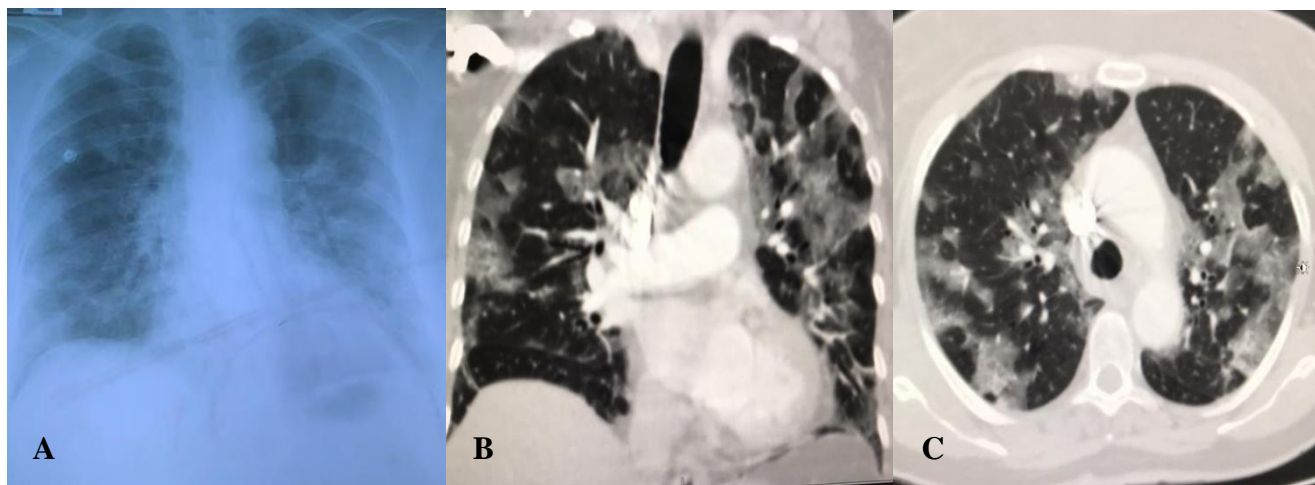
COVID-19 pneumonia in a 66-year old Honduran female with false negative RT-PCR but typical tomography pattern

Neumonía por COVID-19 en una hondureña de 66 años con RT-PCR falso negativo, pero con patrón tomográfico típico

Carlos Aguilar,^{a,1} Nora Maradiaga,^a Nelson Menocal,^b Suyapa Sosa,^a Wendy Moncada,^a Ana Betanco,^a Dennis Rodríguez,^a Byron Degrández,^a Luisa Rodríguez,^a Gerardo Mejía^a

^aInstituto Nacional Cardiopulmonar, Tegucigalpa, Honduras

^bCentro de Imagen y Diagnóstico Hondureño, Tegucigalpa, Honduras



During the first weeks of the SARS-CoV-2 pandemic in Honduras, a 66-year-old female patient was admitted to the ICU with a 5-day history of cough, fever, and respiratory distress. She had contact with a COVID-19 patient in previous days. The chest radiograph showed signs of bilateral ground-glass opacities (A). Since the RT-PCR was negative, a computed tomography angiography was done at day 7 to rule out a pulmonary embolism. This showed a diffuse, patchy, bilateral increase in density with ground-glass opacities, poorly defined edges, and slight predominance in subpleural regions (B and C). There was no evidence of a pulmonary thromboembolism. The swab test was repeated at day 7, resulting positive. In this case, the clinical and CT findings were highly suggestive before RT-PCR confirmed the diagnosis. This is the first COVID-19 case with a false negative PCR test in our hospital. She recovered fully.

Bibliographic References

Xie X, Zhong Z, Zhao W, Zheng C, Wang F, Liu J. (2020). Chest CT for typical 2019-nCoV pneumonia: Relationship to Negative RT-PCR Testing. *Radiology*, 12:200343. [Epub ahead of print]

¹ Autor corresponsal: craguilar27@yahoo.com, Instituto Nacional Cardiopulmonar, Tegucigalpa, Honduras

Historia del Artículo: Recibido: 30 de marzo 2020; Revisado: 30 de marzo 2020; Aceptado: 14 de abril 2020; Disponible en línea: 30 abril 2020

Este es un artículo de acceso abierto disponible en <https://doi.org/10.5377/innovare.v9i1.9656>

© 2020 Autores y UNITEC. Este es un artículo de acceso abierto bajo la licencia <http://creativecommons.org/licenses/by-nc-nd/4.0>.