

## Case report

# Eisenmenger Syndrome Associated with an *ostium secundum* Atrial Septal Defect in an Adult Woman

DOI: 10.5377/alerta.v7i1.16816

Claudia Sarai Alfaro María<sup>1</sup>, Marcela Alejandra Rodas Cruz<sup>2\*</sup>, Jesús Fernando Henríquez Alvarado<sup>3</sup>, Jonathan Alfonso Monterrosa Osorio<sup>4</sup>

1,3-4. San Rafael National Hospital, La Libertad, El Salvador.


2. Central American Laboratories Inc., San Salvador, El Salvador.

\*Correspondence

✉ m.alerodas@gmail.com

1.  0009-0009-0369-1226

2.  0000-0002-6889-6048

3.  0009-0001-5132-5484

4.  0009-0003-4915-5644

## OPEN ACCESS

**Síndrome de Eisenmenger secundario a comunicación interatrial tipo *ostium secundum* en mujer adulta**

### Suggested citation:

Alfaro María CS, Rodas Cruz MA, Henríquez Alvarado JF, Monterrosa Osorio JA. Eisenmenger Syndrome Associated with an *ostium secundum* Atrial Septal Defect in an Adult Woman. Alerta. 2024;7(1):12-17. DOI: 10.5377/alerta.v7i1.16816

### Received:

August 7, 2023.

### Accepted:

January 8, 2024.

### Published:

January 25, 2024.

### Authors contribution:

CSAM<sup>1</sup>, JFHA<sup>3</sup>, JAMO<sup>4</sup>: study conception. MARC<sup>2</sup>, JAMO<sup>4</sup>: manuscript design. CSAM<sup>1</sup>, MARC<sup>2</sup>, JFHA<sup>3</sup>, JAMO<sup>4</sup>: literature search, writing, revising and editing.

### Conflicts of interest:

No conflicts of interest.

### Abstract

Eisenmenger syndrome is the most severe form of pulmonary arterial hypertension secondary to an unrepaired congenital heart disease. Despite the low prevalence, it remains a challenge for the public health service of developing countries due to the complexity of the treatment. **Case presentation.** A female patient without known medical history, who consults with dyspnea on exertion and polycythemia. **Treatment.** A transesophageal echocardiogram was performed, showing an *ostium secundum* atrial septal defect and severe pulmonary arterial hypertension with a right-left shunt. Supplemental oxygen was administered and pharmacological treatment was started. **Outcome.** The patient presented remarkable clinical improvement to dyspnea, she was discharged with medical reference to the Adult Congenital Heart Disease clinic at Rosales National Hospital.

### Keywords

Eisenmenger Complex, Pulmonary Arterial Hypertension, Heart Defects, Congenital, Polycythemia.

### Resumen

El síndrome de Eisenmenger es la forma más severa de hipertensión arterial pulmonar secundaria a defectos cardíacos congénitos no reparados, aunque su prevalencia es baja, continúa siendo un reto para los sistemas de salud de los países en vías de desarrollo por su complejidad en el manejo. **Presentación del caso.** Paciente femenina sin antecedentes médicos conocidos quien consulta por disnea relacionada a los esfuerzos y policitemia. **Intervención terapéutica.** Se realiza ecocardiograma transesofágico que arroja la presencia de defecto interatrial tipo *ostium secundum* e hipertensión arterial pulmonar severa, con cortocircuito de derecha a izquierda, se inicia oxigenoterapia y terapia farmacológica. **Evolución clínica.** Paciente permaneció ingresada presentando notable mejora a la disnea, se le dio de alta con referencia a la clínica de cardiopatías congénitas del adulto en Hospital Nacional Rosales.

### Palabras clave

Complejo de Eisenmenger, Hipertensión Arterial Pulmonar, Cardiopatías Congénitas, Policitemia.

## Introduction

Eisenmenger syndrome (ES) is the most severe presentation of pulmonary arterial hypertension; clinically, it is characterized by the presence of an unrepaired congenital heart defect (CHD) that allows the presence of a shunt between the systemic and

pulmonary circulation as a ventricular septal defect and atrial septal defect.<sup>1</sup>

In Europe, ES shows a reported prevalence of 1 to 5.6 % in cohorts of patients with CHD.<sup>2</sup> In El Salvador, there was a registry of 70 000 newborns during 2017, and 1173 presented CHD, which implies a risk for the development of ES.<sup>3</sup>

It is considered a systemic disease with multi-organ involvement, which explains the various manifestations presented by patients suffering from it, such as exercise intolerance, erythrocytosis, dyspnea, central and peripheral cyanosis, digital clubbing, headaches, cerebrovascular accidents, brain abscesses, hemorrhages, thrombosis, iron deficiency, anemia, hyper-viscosity syndrome, among others.<sup>4</sup>

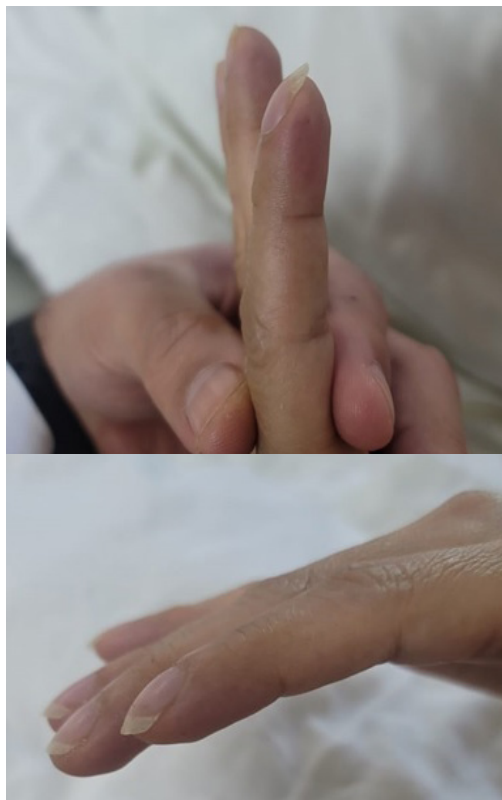
The treatment of patients with ES is limited to palliative management due to the difficulty of accessing cardiopulmonary transplantation as a curative treatment; however, there are advances in pharmacological management with antiarrhythmic drugs, prostacyclin analogs, and diuretics, among others.<sup>5</sup>

## Case presentation

This report is about a 37 year-old woman who consulted with a month history of dyspnea related to moderate physical exertion that decreased with repose, and during the last 24 hours, had progressed to dyspnea on minimal exertion and was accompanied by acrocyanosis, fatigue, generalized weakness, oppressive precordial pain associated with physical activity, which improved with rest. Palpitations, syncope, or other symptoms, were ruled out. The patient went to a private practice and was referred to the San Rafael National Hospital for inpatient management due to the identification of polycythemia.

There was a history of two previous pregnancies, with no other diagnosed medical conditions. On exploring the health medical history, the patient described episodes of perioral cyanosis since childhood that subsided without having received specific treatment.

In the physical evaluation, tachypnea was identified, with diaphoresis and perioral cyanosis. In addition, the patient exhibited a heart rate of 100 bpm, respiratory rate of 22 rpm, blood pressure of 90/60 mmHg, oxygen saturation of 70 % at room temperature; There was perioral cyanosis, acrocyanosis and hippocratic fingers (Figure 1), neck with bilateral jugular ingurgitation at 90° to the edge of the jaw, decreased vesicular murmur was auscultated, with bilateral basal crepitant rales in lung fields, regular heart rhythm, end-systolic murmur in mitral focus III/IV with Rivero-Carvalho sign, flat abdomen, painful on palpation in the right upper quadrant, liver 1 cm below the costal margin, positive hepatojugular reflux.



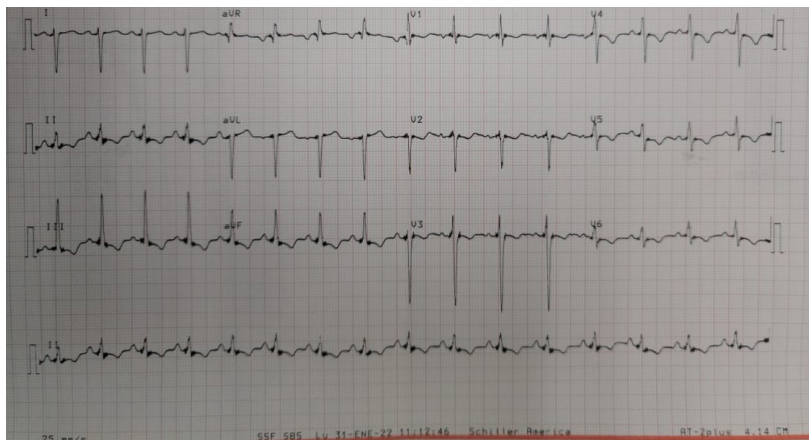
**Figure 1.** Finger clubbing

## Therapeutic intervention

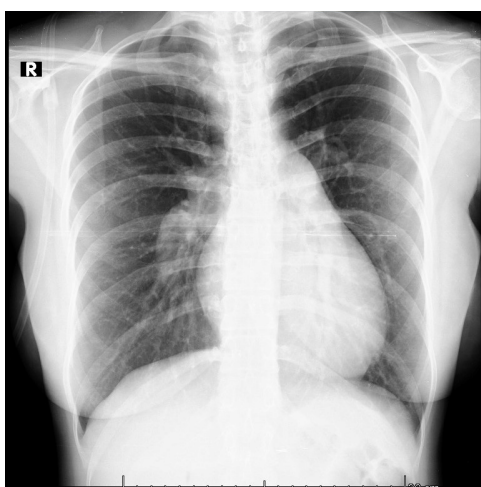
The patient was transferred to the area of maximum urgency, where management began with supplemental oxygen at 15 L/min with a reservoir mask; a hemogram was taken (Table 1), polycythemia was detected, and an electrocardiogram (Figure 2) (Figure 3) reflected an enlarged cardiac silhouette.

**Table 1.** Admission hemogram taken at the maximum urgency unit of the San Rafael National Hospital

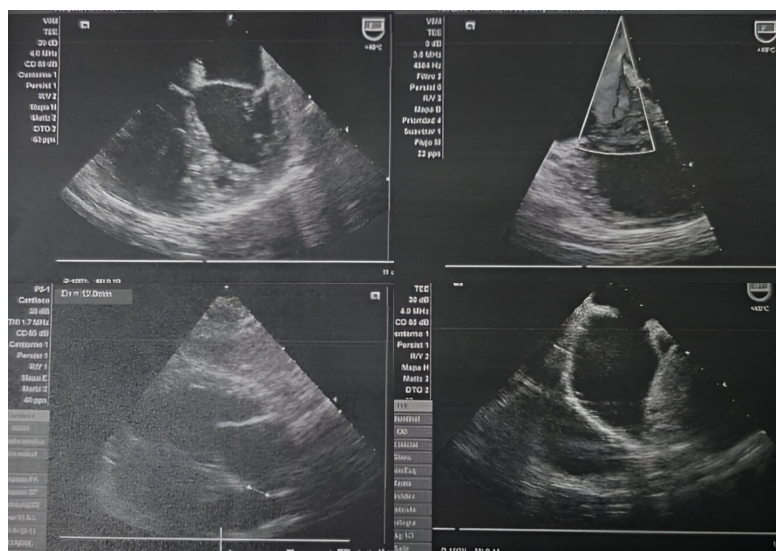
Results	
Red line	
Hemoglobine	18.5 g/dL
Hematocrit	55.6 %
Mean corpuscular volume	89.5 µg
Mean corpuscular hemoglobin	29.8 pg
Erythroblasts	0.75 %
White line	
White blood cells	5.91 ×10 <sup>3</sup> µL
Neutrophils	72.7 %
Lymphocytes	22.0 %
Platelet line	
Platelets	247x103/µl
Mean platelet volume	10.7 fL



**Figure 2.** Electrocardiogram of 12 leads. Taken in maximum urgency unit. Reports: sinus rhythm, heart rate 100 bpm, electrical axis deviation to the right, high voltage P wave, R wave > 6 mm in V1, Lewis index = -25, Cabrera index = 0.87, suggestive of right ventricular hypertrophy



**Figure 3.** Chest X-ray taken in the maximum urgency unit. Anteroposterior projection, showing magnification of the cardiac silhouette by projection. Dilatation of the pulmonary artery trunk and prominent right interlobar artery with decreased peripheral pulmonary vasculature. Pattern of pulmonary hypertension



**Figure 4.** Transesophageal echocardiogram. Interatrial septum with orifice measuring 22 mm, with wide right-to-left shunt, *ostium secundum* type. Tricuspid valve with wide regurgitation jet that goes to the interatrial septum and reaches the septal defect

After the patient was stabilized, she was transferred to the intermediate care unit, with heart rate of 87 bpm, respiratory rate of 16 rpm, blood pressure of 100/60 mmHg, oxygen saturation of 85 % with O<sub>2</sub> with reservoir mask with FIO<sub>2</sub> 100 %. Arterial blood gases reported moderate respiratory distress syndrome (Table 2), due to which furosemide 20 mg intravenous (IV) every eight hours and acetylsalicylic acid 100 mg orally every day were started.

**Table 2.** Arterial blood gas

Parameter	Value
pH	7.45
paCO <sub>2</sub>	17 mmHg
pO <sub>2</sub>	39 mmHg
SO <sub>2</sub>	77 %
HCO <sub>3</sub>	11.8 mmHg
BE	-9,6 mmol/L
TCO <sub>2</sub>	12.6 mmol/L

The transthoracic echocardiogram taken on the second day of admission reported left chambers with normal diameters, dilated right chambers. It was not possible to define the continuity defect in the interatrial septum, and it was also difficult to define a shunt due to the presence of severe tricuspid regurgitation that collided with the septum. The pericardium was reported normal, and the aortic and mitral valves were functional with moderate pulmonary valve dysfunction; normal systolic function, left ventricular ejection fraction of 53 %, and pulmonary artery systolic pressure of 88 mmHg, were found

After four days, a transesophageal ultrasound was performed, which showed an *ostium secundum*-type lesion (Figure 4).

## Clinical evolution

The patient was maintained on supplemental oxygen through a reservoir mask at 15 L/min, and treatment was started with sildenafil 25 mg orally every eight hours in the second day of admission, as well as a single dose of digoxin (0.25 mg IV). The patient presented favorable evolution with improved dyspnea at rest, and oxygen saturation between 85 and 90 %.

The patient continued with furosemide 20 mg IV every eight hours and acetylsalicylic acid 100 mg orally every day. Phlebotomies of 200 mL were administered with a volume replacement of 200 mL of 0.9 % saline solu-

tion every day for five days. Subsequently, after 11 days of hospital stay, the patient was transferred to the intermediate care unit, where oxygen therapy was reduced to a minimum of 3 L/min. After fifteen days of management, she was discharged from the hospital with furosemide 40 mg orally every 12 hours, sildenafil 25 mg every eight hours, and supplemental oxygen at 3 L/min with nasal cannula. Finally, the patient was referred to the Adult Congenital Heart Disease Clinic of the Rosales Nacional Hospital for follow-up.

## Clinical diagnosis

Eisenmenger syndrome associated with an unrepaired *ostium secundum* atrial septal defect.

## Discussion

Eisenmenger's syndrome consists of a variety of symptoms such as dyspnea, cyanosis, precordial pain, clubbed fingers, syncope, hemoptysis, etc., which are the result of untreated CHD. Any CHD that leads to the development of pulmonary arterial hypertension can cause SE. It usually occurs in atrioseptal defects, ventricular septal defects, atrioventricular defects, and persistent ductus arteriosus.<sup>5</sup>

ES is a rare clinical entity that affects patients who do not have adequate access to health services in rural areas or developing countries, in which large CHD can go undetected for years.<sup>4</sup> In the case presented, the patient presented symptomatology congruent with ES without a history of CHD, which delayed the diagnosis, with the social risk factors described.

The pathophysiology that leads to the ES development is a consequence of left-to-right shunts, which cause an increase in pulmonary vascular resistance and the alteration of vasoactive mediators triggering vasoconstriction and vascular remodeling, which consists of smooth muscle proliferation and thrombosis caused by an increase in blood flow resistance. Consequently, there is a chronic increase in pulmonary pressure and right ventricular pressure when pulmonary artery pressure exceeds systemic pressure, thus reversing to a right-to-left shunt and establishing ES.<sup>5</sup>

The right-to-left shunt allows deoxygenated blood to enter the systemic circulation, causing systemic manifestations such as erythrocytosis, cyanosis, exercise intolerance, palpitations, acropaquia, jugular ingurgitation, lower limb edema, livedo reticularis, among others.<sup>6</sup>

Hypoxia and chronic cyanosis generate multiorgan compromise, which produces secondary erythrocytosis as a maladaptive response to hypoxemia; this adaptation triggers iron deficiency and hyper-viscosity syndrome that increases morbidity and the frequency of patient hospitalization.<sup>7</sup>

On the other hand, compensated erythrocytosis generates a balance in iron and ferritin levels with elevated hematocrit; in these patients VHS symptoms are mild or nonexistent, and the risk of presenting thrombotic events is low, as long as hematocrit levels do not exceed 70%.<sup>8</sup> Whereas, in patients with decompensated erythrocytosis, a balance between increased hematocrit levels and iron reserves is not achieved causing moderate to severe VHS symptoms.<sup>9</sup> The highest hematocrit recorded in the case presented was 56.9%, with a low risk of VHS and thrombotic events. Iron and ferritin levels were not identified.

In terms of diagnosis, some studies, such as the electrocardiogram, have a complementary role, allowing early detection of arrhythmias, right ventricular hypertrophy, and the presence of right bundle branch block. Frequently, the following can be identified: right axis deviation, presence of pulmonary P wave, QTc prolongation, ST depression/T inversion in the right precordial leads V1-V4, and leads DII, DIII, and aVF.<sup>10</sup> Similarly, transthoracic echocardiography, which is the most relevant monitoring tool, allows identification of cardiac morphology and function.<sup>10</sup> In this case in question, an atrial septal defect was suspected at the level of its middle portion with right-to-left shunt, which was confirmed by transesophageal echocardiography.

In the same way, cardiac magnetic resonance imaging allows the evaluation of ventricular function and its volumes, being a useful non-invasive tool to determine the pulmonary flow to systemic flow ratio, it is not available in all healthcare centers. It should not be conducted on unstable, dyspneic or oxygen-dependent patients.<sup>11</sup>

Finally, right cardiac catheterization, which is considered the gold standard, allows confirmation of the diagnosis and differentiation between pulmonary hypertension of other origin since it is a direct hemodynamic evaluation; patients with SE have a higher mean pulmonary artery pressure and pulmonary vascular resistance than patients with idiopathic pulmonary arterial hypertension.<sup>12</sup>

The key to the treatment of patients with ES lies in avoiding alteration of the balance of the pathophysiological state, which implies close monitoring by a multidisci-

plinary team focused on the prevention and management of complications.<sup>13</sup> Supplemental oxygen does not reduce the risk of mortality or increase tissue oxygenation, and can cause dry mucous membranes in the upper airway, predisposing patients to epistaxis and hemoptysis. It is recommended when an increase in oxygen saturation in the bloodstream and a consistent improvement in symptoms are present.<sup>14</sup>

Elevated hemoglobin values in these patients should not be treated like other types of polycythemia; routine phlebotomies are associated with adverse outcomes such as iron deficiency and increased risk of thrombotic events. Selected patients may benefit from occasional phlebotomies with isovolumetric replacement, for example, patients with moderate to severe symptoms of hyperviscosity or hematocrit > 65 %.<sup>15</sup>

Anticoagulation therapy is not recommended for all patients as it has not been shown to reduce mortality and may increase the risk of bleeding. Hence, it is recommended only for patients with hemostatic risk factors such as atrial fibrillation, atrial flutter, prosthetic valves, blood stasis, and absence of hemoptysis.<sup>16</sup>

Drug therapy is based on three different metabolic pathways, endothelin receptor antagonists, phosphodiesterase-5 inhibitors, and prostacyclins. Bosentan, an endothelin receptor antagonist, is the first drug to improve exercise tolerance and decrease mean pulmonary arterial pressure and pulmonary vascular resistance. It is considered first-line treatment, a result comparable to those shown by phosphodiesterase-5 inhibitors such as sildenafil<sup>17</sup>. Also, prostacyclins, a third-line treatment, prevent the risk of infection and paradoxical thrombotic events.<sup>18</sup>

Surgical intervention to repair CHD is recommended in the terminal phase of the disease, with variable results.<sup>19</sup> On the other hand, cardiopulmonary transplantation is the definitive treatment accompanied by pharmacological treatment.<sup>17</sup>

Early detection of CHD and intervention before the onset of irreversible alterations lead to a better quality of life; in this regard, it is recommended that adequate cardiac screening be implemented in newborns and children who present symptoms suggestive of heart disease, and adequate education to parents or caregivers to identify the warning signs and symptoms.<sup>20</sup>

## Acknowledgements

To the cardiology team of the San Rafael National Hospital for their invaluable

contribution to the accurate diagnosis of the patient.

## Funding

The authors declare there are not external funds for this work.

## References

1. Benlamkaddem S, Bouyermane F, Doughmi D, Berdai MA, Harandou M. Fatal Association of Eisenmenger Syndrome and Severe Preeclampsia. *Cureus*. 2023 Apr 19. DOI: [10.7759/cureus.37836](https://doi.org/10.7759/cureus.37836)
2. Flores Molina V. Perfil Epidemiológico y Clínico de las Malformaciones Cardíacas Congénitas, en pacientes ingresados en el servicio de Neonatología del Hospital Nacional de Niños Benjamin Bloom del 1° de Enero del 2016 al 31 de Diciembre del 2018. Tesis de posgrado. San Salvador: Universidad de El Salvador; 2019. Available at: <https://docs.bvsalud.org/biblioref/2020/10/1127641/13-11106181.pdf>
3. Calderón-Colmenero J, Sandoval Zárate J, Beltrán Gámez M. Hipertensión pulmonar asociada a cardiopatías congénitas y síndrome de Eisenmenger. *Arch. Cardiol. México*. 2015;85(1):32-49. DOI: [10.1016/j.acmx.2014.11.008](https://doi.org/10.1016/j.acmx.2014.11.008)
4. Arvanitaki A, Gatzoulis MA, Opatowsky AR, Khairy P, Dimopoulos K, Diller G-P, et al. Eisenmenger Syndrome. *J. Am. Coll. Cardiol*. 2022;79(12):1183-1198. DOI: [10.1016/j.jacc.2022.01.022](https://doi.org/10.1016/j.jacc.2022.01.022)
5. Basit H, Wallen TJ, Sergent BN. Eisenmenger Syndrome. National Library of Medicine. 2023. Date of citation: 2 de agosto de 2023. Available at: <https://www.ncbi.nlm.nih.gov/books/NBK507800/>
6. Kellish AS, Hakim A, Soal V, Hassinger G, Gable B. Where on the Differential Is Eisenmenger Syndrome in a Patient Without Prior Cardiopulmonary Disease? *Cureus*. 2020 Jun 8. DOI: [10.7759/cureus.8509](https://doi.org/10.7759/cureus.8509)
7. Martin-Garcia AC, Arachchillage DR, Kempny A, Alonso-Gonzalez R, Martin-Garcia A, Uebing A, et al. Platelet count and mean platelet volume predict outcome in adults with Eisenmenger syndrome. *Heart*. 2018;104(1):45-50. DOI: [10.1136/heartjnl-2016-311144](https://doi.org/10.1136/heartjnl-2016-311144)
8. Moons P, Canobbio MM, Budts W. Eisenmenger Syndrome: A Clinical Review. *Eur. J. Cardiovasc. Nurs*. 2009;8(4):237-245. DOI: [10.1016/j.ejcnurse.2009.05.004](https://doi.org/10.1016/j.ejcnurse.2009.05.004)
9. Van De Bruaene A, Delcroix M, Pasquet A, De Backer J, De Pauw M, Naeije R, Vachiery J-L, Paelinck B, Morissens M, Budts W. Iron deficiency is associated with adverse

- outcome in Eisenmenger patients. *Eur. Heart J.* 2011;32(22):2790-2799. DOI: [10.1093/eurheartj/ehr130](https://doi.org/10.1093/eurheartj/ehr130)
10. Valkovicova T, Kaldararova M, Reptova A, Bohacekova M, Bacharova L, Hatala R, Simkova I. Eisenmenger syndrome - an electrocardiographic and echocardiographic assessment of the right ventricle. *Bratisl. Med. J.* 2018;119(06):321-329. DOI: [10.4149/BLL\\_2018\\_060](https://doi.org/10.4149/BLL_2018_060)
  11. Arvanitaki A, Giannakoulas G, Baumgartner H, Lammers AE. Eisenmenger syndrome: diagnosis, prognosis and clinical management. *Heart.* 2020;106(21):1638-1645. DOI: [10.1136/heartjnl-2020-316665](https://doi.org/10.1136/heartjnl-2020-316665)
  12. Gong C, He S, Chen X, Wang L, Guo J, He J, Yin L, Chen C, Han Y, Chen Y. Diverse Right Ventricular Remodeling Evaluated by MRI and Prognosis in Eisenmenger Syndrome With Different Shunt Locations. *J. Magn. Reson. Imaging.* 2022;55(5):1478-1488. DOI: [10.1002/jmri.27791](https://doi.org/10.1002/jmri.27791)
  13. Diller G-P, Lammers AE, Oechslin E. Treatment of adults with Eisenmenger syndrome—state of the art in the 21st century: a short overview. *Cardiovasc. Diagn. Ther.* 2021;11(4):1190-1199. DOI: [10.21037/cdt-21-135](https://doi.org/10.21037/cdt-21-135)
  14. Chaix M-A, Gatzoulis MA, Diller G-P, Khairy P, Oechslin EN. Eisenmenger Syndrome: A Multisystem Disorder—Do Not Destabilize the Balanced but Fragile Physiology. *Can. J. Cardiol.* 2019;35(12):1664-1674. DOI: [10.1016/j.cjca.2019.10.002](https://doi.org/10.1016/j.cjca.2019.10.002)
  15. Dulac Y. Traitements conventionnels et prise en charge globale. *Presse Médicale.* 2009;38:1S14-1S17. DOI: [10.1016/S0755-4982\(09\)73419-0](https://doi.org/10.1016/S0755-4982(09)73419-0)
  16. Giannakoulas G, Boutsikou M. The Gordian knot of thromboembolism in congenital heart disease: Table 1. *Heart.* 2015;101(19):1523-1524. DOI: [10.1136/heartjnl-2015-308045](https://doi.org/10.1136/heartjnl-2015-308045)
  17. Gatzoulis MA, Landzberg M, Beghetti M, Berger RM, Efficace M, Gesang S, *et al.* Evaluation of Macitentan in Patients With Eisenmenger Syndrome: Results From the Randomized, Controlled MAESTRO Study. *Circulation.* 2019;139(1):51-63. DOI: [10.1161/CIRCULATIONAHA.118.033575](https://doi.org/10.1161/CIRCULATIONAHA.118.033575)
  18. Hjortshøj CS, Gilljam T, Dellgren G, Pentikäinen MO, Möller T, Jensen AS, *et al.* Outcome after heart-lung or lung transplantation in patients with Eisenmenger syndrome. *Heart.* 2020;106(2):127-132. DOI: [10.1136/heartjnl-2019-315345](https://doi.org/10.1136/heartjnl-2019-315345)
  19. Manuel L, Freeman L, Nashef SA. Surgery for Eisenmenger syndrome: time for a rethink? *J. R. Soc. Med.* 2019;112(12):512-513. DOI: [10.1177/0141076819877551](https://doi.org/10.1177/0141076819877551)
  20. Barradas-Pires A, Constantine A, Dimopoulos K. Preventing disease progression in Eisenmenger syndrome. *Expert Rev. Cardiovasc. Ther.* 2021;19(6):501-518. DOI: [10.1080/14779072.2021.1917995](https://doi.org/10.1080/14779072.2021.1917995)