

The prelacrimal approach in maxillary sinus pathologies

DOI: 10.5377/alerta.v7i2.17569

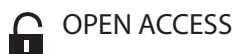
Javier Isaac Molina Velásquez

Specialities Consulting Services, Otorhinolaryngology. Salvadoran Social Security Institute (ISSS). San Salvador, El Salvador.

Correspondence

✉ javier_molina100@hotmail.com

© 0000-0002-0520-2707



OPEN ACCESS

Abordaje prelacrimal en las patologías del seno maxilar

Suggested citation:

Molina Velásquez JI. The prelacrimal approach in maxillary sinus pathologies. *Alerta*. 2024;7(2):212-213. DOI: 10.5377/alerta.v7i2.17569

Editor:

Nadia Rodríguez.

Received:

January 19, 2024.

Accepted:

June 27, 2024.

Published:

July 24, 2024.

Author contribution:

JIMV: study conception, manuscript design, literature search, data collection, data analysis writing, revising and editing.

Conflict of interests:

The author declared no conflict of interests.



© 2024 by the author. This is an open access article distributed under the terms and conditions of the Creative Commons Attribution (CC BY) license (<https://creativecommons.org/licenses/by/4.0/>).

Dear Editor.

The knowledge of different techniques for the management of pathologies in medical specialties is essential. Such is the case of maxillary sinus pathology, which is very frequent in the field of otorhinolaryngology, and in the area of endoscopic nasosinus surgery, it is essential to perform an uncinectomy and maxillary antrostomy. Conventional endoscopic sinus surgery can effectively treat maxillary sinus pathologies; however, some conditions may be difficult to address. It is essential to develop the relevant needed skills to employ various approaches for treating these diseases.

The prelacrimal endoscopic approach to the maxillary sinus is a recent proposal. Access to the maxillary sinus through this technique is easily achieved, without modifying the anatomy of the inferior turbinate and the nasolacrimal duct.ⁱ

It is relevant to remember the anatomy of the floor of the maxillary sinus, which is formed by the alveolar process of the maxilla; this close anatomical relationship forms an interface for therapeutic management with the collaboration of rhinologists, maxillofacial surgeons and dentists.ⁱ The development of nasal endoscopy and high-resolution imaging techniques enabled nasal endoscopic surgery to become the most widely used and most effective treatment for many disorders of the maxillary sinus; however, for anatomical reasons, such as the positions of the anterior and medial walls and the alveolar process of the maxillary sinus, many pathologies are not easily visible and manageable, thus making

resection through the traditional endoscopic approach difficult.ⁱⁱ

Through the pre-lacrimal approach, access to the maxillary sinus is achieved anterior to the nasolacrimal duct in an oblique way, and through this, adequate control of the anterior and lateral walls is achieved, with optics of 0 and 45 degrees. This innovative rhinological technique has demonstrated advantages over traditional external and endoscopic methods, providing optimal surgical access to the anterior maxillary sinus.ⁱ

The pre-lacrimal recess is an area with boundaries defined by the inner wall of the maxillary sinus, the front wall of the maxillary sinus, the infraorbital region, and the level of the nasolacrimal duct.ⁱⁱⁱ From the above, it is clear that the pre-lacrimal approach involves the removal of 2 to 3 mm of anterior lacrimal duct bone with retraction and careful displacement of the medial maxillary wall during surgery.ⁱⁱⁱ

Simmen *et al.* proposed that a distance of > 7 mm (Type 3) allows the pre-lacrimal approach to be performed with little difficulty, a distance of > 3 - 7 mm (Type 2) allows the pre-lacrimal approach to be performed with partial dislocation of the lacrimal duct, and a distance of 0 - 3 mm (Type 1) will require a significant amount of bone removal, dislocation of the lacrimal sac, and a smaller pre-lacrimal window, making this approach less feasible.ⁱⁱⁱ

The technique involves performing a curvilinear incision in the lateral nasal wall, anterior to the head of the inferior turbinate, then entering the maxillary sinus through a bony cut anterior to the lacrimal duct with

a chisel, preserving the lacrimal duct. The mucosa medial to the bone and the lateral nasal wall is dissected subperiosteally until reaching the head of the inferior turbinate and the anterior border of the maxillary sinus ostium. The bony canal of the lacrimal duct is removed with this dissected bony lateral nasal wall. The bony remnant of the lateral nasal wall resulting from the connection of the anterior and medial portion of the maxillary sinus is excised using Kerrison forceps. The medial retraction of the tear duct and the remaining lateral nasal wall remnant containing the inferior turbinate allows direct visualization and surgical access to the anterior wall and floor of the maxillary sinus.ⁱⁱⁱ

The pre-lacrimal approach is recommended for treating severe pathologies of the maxillary sinus, particularly those originating in the anterior wall, lateral wall, or floor of the maxillary sinus. This approach has exhibited a lower recurrence rate when compared to maxillary antrostomy.^{iv}

A relevant consideration to keep in mind is to avoid removing the adherent mucosa when performing a pre-lacrimal approach in cases of inflammation or infectious diseases, such as odontogenic sinusitis, fungal sinusitis, chronic sinusitis, and nasal polyps.

About the above, it is inferred that the pre-lacrimal approach to the maxillary sinus is a minimally invasive, safe, and effective procedure for pathologies of the maxillary sinus, such as tumors located in the anteroinferior or inferolateral wall or multiple sites of the maxillary sinus junction, including benign tumors originating in the sinonasal cavity, inverted nasal papilloma, hemangioma, fibrous dysplasia, and angiofibroma.^{ii,v}

References

- i. Ananthapadmanabhan S, Noor A, Sritharan N. Prelacrimal Window Approach in the Management of Odontogenic Maxillary Sinusitis from Dental Foreign Body. Mergoni G, editor. *Case Rep. Dent.* 2022;1-6. DOI: [10.1155/2022/1730656](https://doi.org/10.1155/2022/1730656)
- ii. Yu QQ, Guan G, Zhang NK, Zhang XW, Jiang Y, Lian YY, *et al.* Intranasal endoscopic prelacrimal recess approach for maxillary sinus inverted papilloma. *Eur. Arch. Otorhinolaryngol.* 2018;275(9):2297-2302. DOI: [10.1007/s00405-018-5078-1](https://doi.org/10.1007/s00405-018-5078-1)
- iii. Lock PSX, Siow GW, Karandikar A, Goh JPN, Siow JK. Anterior maxillary wall and lacrimal duct relationship in Orientals: CT analysis for prelacrimal access to the maxillary sinus. *Eur. Arch. Otorhinolaryngol.* 2019;276(8):2237-2241. DOI: [10.1007/s00405-019-05446-0](https://doi.org/10.1007/s00405-019-05446-0)
- iv. Mohankumar V, Kannan DS, Narendrakumar V, Kuppuswamy S, Baby AN. A Comparative Study between Endoscopic Prelacrimal Approach and Middle Meatal Antrostomy for Maxillary Sinus Pathologies. *Indian J. Otolaryngol. Head Neck Surg.* 2022;74(1):90-95. DOI: [10.1007/s12070-021-02703-9](https://doi.org/10.1007/s12070-021-02703-9)
- v. Lee JJ, Ahmad ZAM, Kim D, Ryu G, Kim HY, Dhong HJ, *et al.* Comparison Between Endoscopic Prelacrimal Medial Maxillectomy and Caldwell-Luc Approach for Benign Maxillary Sinus Tumors. *Clin. Exp. Otorhinolaryngol.* 2019;12(3):287-293. DOI: [10.21053/ceo.2018.01165](https://doi.org/10.21053/ceo.2018.01165)